



By Frank Caruso, CO

Damage to soft tissue structures generally occurs because too much stress crosses those tissues. This can be acute trauma, such as an inversion ankle sprain, or it can be gradual progressive cumulative trauma, such as posterior tibialis tendon dysfunction (PTTD), Achilles tendinitis, or shin splints.

In either case, much is now known about the biomechanical properties of soft tissue healing. Essentially there are three choices:

1. uncontrolled stress
2. immobilization to eliminate all stress
3. controlled stress

Conceptually, controlled stress would seem to be the ideal environment for orthotic management of PTTD. How could that be accomplished?

Uncontrolled stress is usually the condition that leads to the injury in the first place.¹⁻³ When soft tissues are over-taxed due to any number of factors, they can be subjected to micro-trauma that disrupts those muscles and tendons. That trauma can trigger the body's healing response to trauma, including increased vascularization of the traumatized area to deliver more healing nutrients to the injured component. Concurrently, however, edema will settle in to the area of injury secondary to the disruption of those soft tissues. This edema can occlude blood vessels, thereby inhibiting the healing process.

Immobilization of orthopedic structures has been shown to do two things. It leads to atrophy of the residual structure, including but

A controlled-stress approach to PTTD

not limited to atrophy of muscle/tendon mass, muscle strength, vascularity, osseous structures, articulating surfaces and proprioceptors.⁴ It also causes the collagen fibers needed to facilitate the repair to form intractable hypertrophic scar tissue that lacks strength and elasticity.^{5,6}

We learned in the 1960s and '70s that immobilizing simple ankle sprains led to the ankle "healing" in a weaker condition, and it became more susceptible to re-injury than it was pre-injury.⁷ Remember when it was standard operating procedure to place every grade 3 ankle sprain in plaster immobilization for three to six weeks? Following immobilization, the "chronic ankle" was common and "normal." Regaining intrinsic functional ankle stability post-immobilization was a very elusive goal.

Augustin et al⁸ described outcomes in managing PTTD in an ankle gauntlet style AFO, defining "success" as 90% of patients achieving reduced levels of pain. However, only one patient out of 21 (<5%) in the study was able to discontinue use of the device on one year follow-up because of resolution of symptoms.

Benefits of controlled stress

Controlled stress has been shown to provide the ideal environment for soft tissue healing. The use of continuous passive motion (CPM) machines on post-operative knees is just one example of the application of this concept. The benefits include:

- The collagen fibers that facilitate healing lie down in the orientation of the original structure and take on the properties of the original structure, thereby serving to restore the strength and elasticity of the original structure to its pre-injury state.⁶
- Atrophy of residual structure mass, strength, vascularity and proprioceptive properties is minimized.⁹
- Structural integrity of articulating surfaces is maintained.
- Edema is reduced secondary to the "muscle pump" effect whereby muscle contraction during ambulation squeezes (pumps) fluids proximally away from the site of injury

Conceptually, therefore, controlled stress would seem to be the ideal environment for orthotic management of PTTD. How could that be accomplished? There are both "local" and "global" stresses that need to be managed in PTTD patients. The "local" issues relate to biomechanical dysfunction in the foot, which can lead to uncontrolled stress on the posterior tibialis muscle/tendon complex. The "global" issues relate to dynamic top-down gravitational and ground reaction forces on that same complex.

First we can review the normal function of the posterior tibialis muscle. The posterior tibialis muscle is activated through the stretch reflex at initial contact.¹⁰ In this phase, it serves to decelerate gravitational forces driving the subtalar joint into valgus, it decelerates valgus collapse of the midfoot, and thereby also decelerates forefoot abduction. It turns off shortly after the loading response, after the forefoot reaches the ground. It is not active during most of midstance as the foot/ankle complex is structurally stable in this phase of gait. It is fired again late in mid-stance as the

tibia progresses over the fixed foot, thereby providing additional decelerating effect of pronatory forces and preparing the foot to reposition into supination for more effective and efficient propulsion during the third rocker. So loading and unloading of the posterior tibialis muscle occurs earlier and later in the closed chain phases of gait when the foot engages the ground and again when it leaves the ground. It is the only dual-phase muscle in the plantar flexor group.

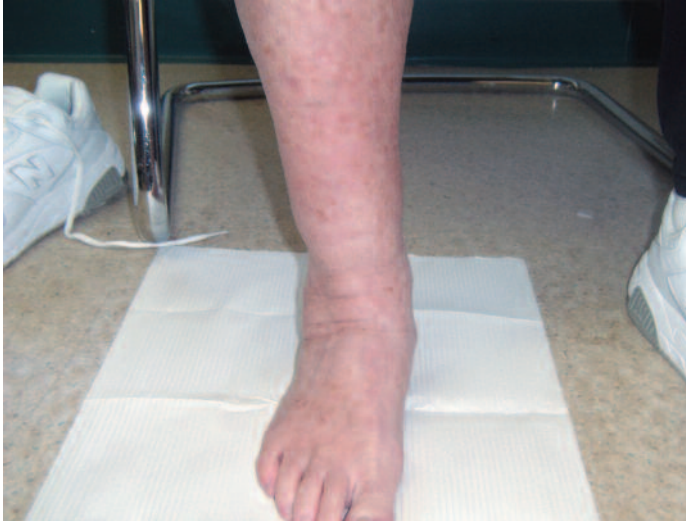

Figure 1. Patient non weight bearing. Anterior view showing Grade 3 PTTD, with subtalar joint swelling and forefoot eversion. (The same patient is featured in all figures.)

PTTD is often associated with adult onset or acquired overpronation. This can be secondary to excessive body weight, diabetes, or overuse in conjunction with athletic activities such as long distance running. As the posterior tibialis muscle tries to maintain medial longitudinal arch height, the unlocking mechanism allows the foot to overpronate in response to gravitational and other external and ground reaction forces². The combination of excessive motion combined with the triggering mechanism firing the posterior tibialis muscle causes undue simultaneous stretch and stress on the PT muscle/tendon complex.

Local orthotic support

Orthotic interventions can be designed to control the causative factors of PTTD while avoiding immobilization. Local orthotic support is required to assist in the management of:

- Deceleration of excessive calcaneal eversion occurring at initial contact
- Deceleration of excessive midfoot collapse, including excessive unlocking of the navicular bone
- Deceleration of excessive forefoot abduction
- Position the foot for improved transition from pronation to supination to facilitate the concentric acceleration of ankle plantar flexion, adduction and inversion in the third rocker.

This local support can be provided by a biomechanical foot orthotic device. The device will need to be firm enough to control abnormal motions occurring secondary to both ground reaction (bottom up) and external (top down) forces being driven through the foot. Designs and materials will depend on the grade of the PTTD, with more rigid control being required as the degree of PTTD increases.

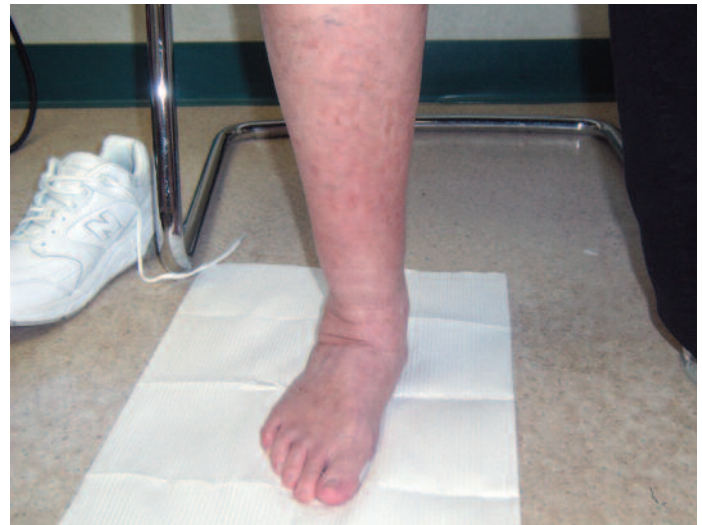

Figure 2. Patient weight bearing, anterior view. Notice marked increase in forefoot eversion, with knee compensated to hyperextension.

For stage I, one could reason that a relatively firm prefabricated foot orthotic shell device would be enough to minimize excessive motions and stresses.¹¹ For stage II, custom semi-rigid control would be more appropriate. For stage III, a fully functional (rigid) biomechanical foot orthotic device or UCB could be justified to control the stresses that lead to the injury. Finally, for a fixed stage IV, a more accommodative device would be appropriate to conform to the deformity and allow support with maximum pressure distribution on soft tissue.

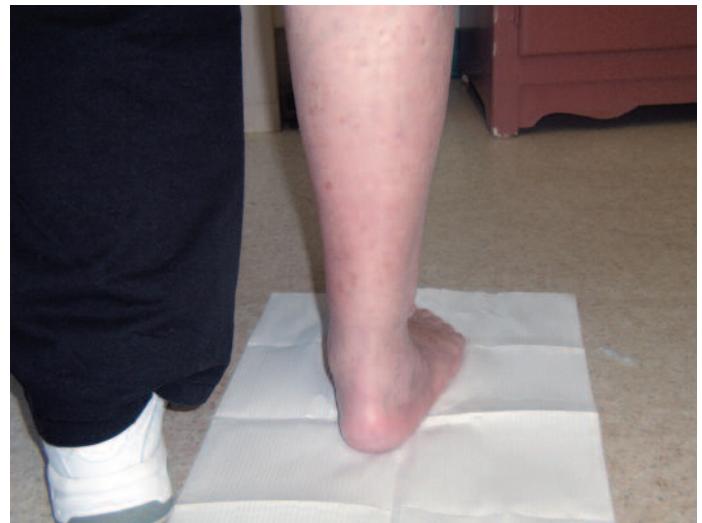

Figure 3. Patient weight bearing, posterior view. Notice increased edema at the Achilles tendon insertion point, too many toes sign common with PTTD Grade 3, and lack of a plantar grade heel, indicating tight Achilles tendon.

Dynamic global orthotic support

For foot biomechanics to function in a controlled stress environment, dynamic global support is then also required to control:

- eccentric deceleration of motion, including ankle valgus, associated with excessive calcaneal eversion, plantarflexion and medial rotation occurring at initial contact
- eccentric deceleration of gravitation and ground reaction forces crossing the foot/ankle complex in the sagittal plane,

especially during the first rocker and into the second rocker

- concentric stress associated with ankle plantar flexion during late second rocker and through the third rocker or propulsive phase of gait

Carbon composite AFOs can be appropriate for the orthotic management of dropfoot. Some of these same devices also offer graded degrees of dynamic support that can be used to take dynamic stress off injured soft tissue and control dynamic proximal motions that a conventional foot orthotic cannot manage. Conceptually these floor-reaction eccentric-concentric orthotic (FRECO) devices minimize abnormal dynamic stress on the PT muscle/tendon complex during the gait cycle, thereby relieving some of the tension normally driven through that complex. They would eccentrically limit eversion and plantarflexion at initial contact, and once “loaded” eccentrically, they would unload or reflect that potential energy by concentrically accelerating inversion and plantar flexion during propulsion.

There are carbon composite FRECO devices available that provide graded (minimal, mid-range and maximum) levels of support. For stage I and early- to mid-stage II, the mid-range device, used with appropriate levels of foot orthotic control discussed earlier, would be appropriate to manage dynamic postures and stresses. For stages III and IV, the maximum support device, also used in conjunction with appropriate levels of foot orthotic control discussed earlier, would provide the additional level of support necessary to alleviate injury causing stresses while allowing an optimal level of stress control to optimize healing.

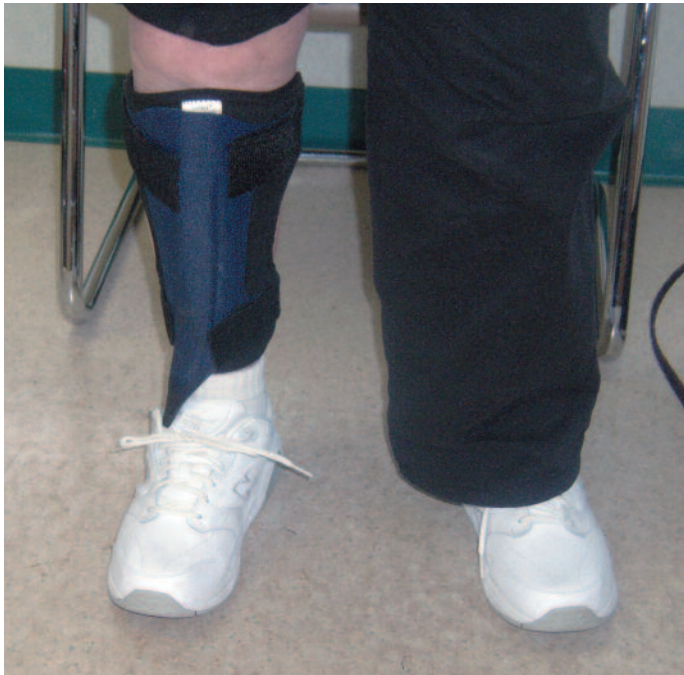


Figure 4. Patient weight bearing, anterior view, with finished FRECO Blue rocker and New Balance walking shoe to aid in third rocker function. Noticed improved forefoot, ankle and knee alignment in stance.

An appropriate FRECO dynamic response orthosis can be combined with the appropriate level of foot orthotic control to create an environment that minimizes stress to a level commensurate with the grade of PTTD, thereby creating a “limited stress” environment to facilitate optimal healing. This concept then facilitates physical therapy that is usually designed to exercise

injured soft tissue injuries within a controlled stress environment. Research by Kulig et al ¹² supports the concept that exercises can more effectively target the posterior tibialis muscle when orthoses and shoes are worn (vs barefoot). Modalities are generally prescribed for reduction of inflammation and edema. These modalities, along with a level of dynamic orthotic intervention commensurate with the level of dysfunction, can combine to lead to earlier pain-free therapeutic rehabilitation and ambulation to strengthen weakened structures.

Conclusion

Avoiding the negative impact of either uncontrolled stress or immobilization, this system of controlled stress, graded to the level of dysfunction, in our experience has been successful in the management of PTTD. In early clinical trials, this system seems to show a decrease in healing time of roughly 50% compared to traditional immobilizing devices. A prospective clinical trial is being organized at this time.

Frank Caruso, CO, is in private practice with Boas Surgical in West Chester, PA. He is an educational consultant for Allard USA and the Pedorthics Program at the Temple University School of Podiatric Medicine in Philadelphia. 

References are available at www.lowerextremityreview.com

Tried ToeOFF for PTTD?

Now you can augment the function of a dysfunctional or overused muscle/tendon complex with a carbon composite dynamic response AFO. Graded energy reflection provides just the right amount of dynamic response to augment muscle function and take stress off of disrupted soft tissue so pain reduction and "controlled stress" healing can occur.

- Ypsilon for mild (incomplete) footdrop
- ToeOFF for complete footdrop, and for moderate soft tissue dysfunctions such as shin splints, Achilles Tendonitis or grades I or II PTTD
- Blue Rocker for footdrop with proximal instabilities, and for more severe soft tissue dysfunctions such as gross ML ankle instabilities or grades III or IV PTTD

